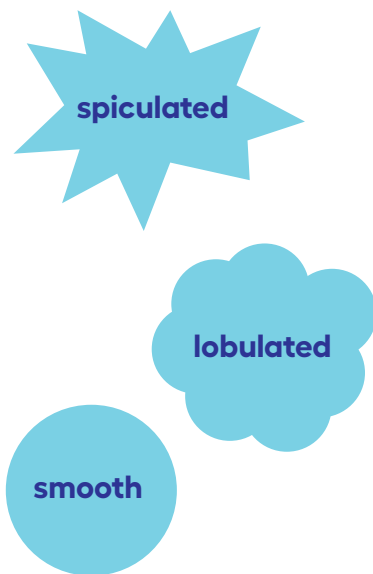


Understanding Lung Nodules

Lung nodules are abnormal spots that may show up on your lung cancer screening scan or other imaging test. Nodules are also called lesions, coin lesions, growths or solitary pulmonary nodules.

Many people have lung nodules by age 50.
Most lung nodules are not cancer, but some lung nodules need more testing.



Nodule Features

Margin

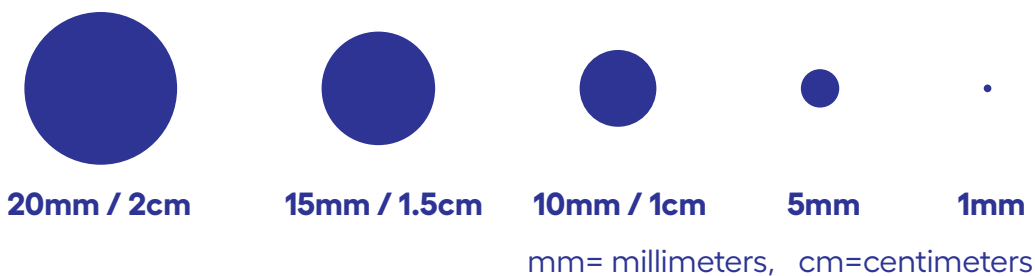
The margin is where the edges of the nodule touch normal lung tissue. The margins of many cancers are uneven, look spiky and are sometimes called spiculated. Most nodules that are not cancer have smooth or rounded margins or look like many round nodules together - also called lobulated.

Density

Density describes how compact or thick something is. A nodule is more dense than normal lung tissue and looks gray on a CT scan. Some nodules have pieces of calcium inside of them which look white, like bone. These are called calcified nodules and are less likely to be cancer.

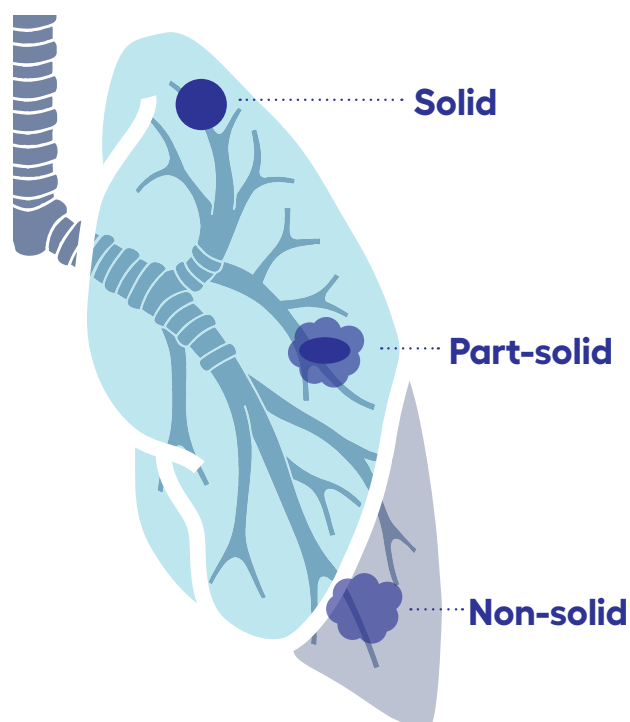
Size

Most nodules that are small in size are not cancer. If you have a nodule and you are at high risk for lung cancer, you may be asked to come back in a year or sooner for another screening test just to make sure it hasn't changed. Smaller nodules are usually managed in this way, while larger nodules may need more testing. Nodule size may be listed as centimeters or millimeters, as shown below.



Consistency

When a nodule is solid, it is called a solid nodule. If it is hazy with no solid parts, it is called a non-solid nodule or a ground glass nodule (GGN) because it looks like ground glass. In some cases, a nodule may have a solid part of it with a hazy part around it. These are called part-solid or semi-solid nodules.



What Next

Nodules that are large, look suspicious, or have changed over time will need more tests or a biopsy. Your healthcare team can help you choose your best next step.

Always contact your healthcare team if you have questions or concerns about your plan.